

## Ultrasound in primary hyperparathyroidism

Peter Vestergaard MD PhD DrMedSc (1), Lars Bolvig Hansen MD (2)

(1) Department of Endocrinology and Internal Medicine, Aarhus University Hospital, Aarhus,  
Denmark

(2) Department of Radiology, Aarhus University Hospital, Aarhus, Denmark

Correspondence:

Peter Vestergaard MD PhD DrMedSc

The Osteoporosis Clinic

Department of Endocrinology and Internal Medicine

Aarhus University Hospital

Tage Hansens Gade 2

DK-8000 Aarhus C

Denmark

Telephone + 45 89 49 76 52

Fax + 45 89 49 76 84

E-mail [p-vest@post4.tele.dk](mailto:p-vest@post4.tele.dk)

**Indications:**

Ultrasound has a central role in patients with primary hyperparathyroidism. It may be used pre- and peroperatively for

- 1) Localisation of parathyroid glands
- 2) Identifying number of supposed pathological glands
- 3) Identifying thyroid pathology and thus be a part of pre-operative planning of the extent of surgery
- 4) Performing biopsies from the thyroid and sometimes also the parathyroid glands

**Technique:**

Pre-operatively ultrasonography is non-invasive. (noget om Hz, billedopløsning, billedstørrelse etc.).

**Anatomy of the parathyroid glands:**

Parathyroid glands usually present as hypoechoic nodules on ultrasonography with no flow on doppler. A normal parathyroid gland is around the size of a rice grain each, i.e. at most a few mm in length and each normal parathyroid weighs around 30 mg [1-4]. Usually four parathyroid glands are present, i.e. the combined weight is around 120 mg. Usually they are localised behind the upper and lower part of the thyroid on the right and left side (Fig. 1). However, the localisation may be rather variable (fig. 2). Also more than four parathyroid glands may be present and ectopic localisation may be seen.

**Ultrasonographic imaging – the pathological parathyroid gland:**

Usually the normal parathyroid glands cannot be visualised. Usually the pathological parathyroid gland appears as a hypoechoic (“black”) nodule behind the thyroid in close contact with the thyroid

capsule. Upon use of the doppler feature no flow is present within the parathyroid gland. The size may be highly variable, and some glands may appear as cystic.

Problems with localisation may occur when the parathyroid glands are not in contact with the thyroid tissue or other tissues which may be used to contrast it against. If the parathyroid gland is localised in the mediastinum it may also be difficult to localise using ultrasonography. Large goitres, and goitres with hypodense areas may also make localisation of parathyroid glands difficult [5]. Usually the parathyroids may be visualised with ultrasonography if they are more than 8-10 mm in diameter.

The sensitivity of ultrasonography [5; 6] may be highly variable depending on size of the parathyroids and whether or not the parathyroids are in close contact with the thyroid. In one series potentially pathological parathyroid glands were localised in 41 of 69 patients (59%) [6], and of these 41, 38 (93%) were correctly localised using the surgical findings as gold standard [6], i.e. the true positive glands were  $38/69=55\%$ .

To be able to do biopsies it is recommended that a parathyroid scintigraphy (sestamibi-scintigraphy) is performed before the ultrasonography is performed.

### **Thyroid pathology:**

Not only the parathyroids should be visualised, also the thyroid and neck anatomy should be visualised in order to identify any pathological tissues that may need surgical attention during surgery. Especially if hypodense areas ("cold areas") are present in the thyroid on the thyroid phase of a sestamibi-scintigraphy, biopsies of the relevant areas should be considered.

### **Biopsies:**

As mentioned above fine needle aspiration (FNA) biopsies may be considered for thyroid processes. Also histological biopsies of the thyroid may be contemplated.

In some settings biopsies are performed of the parathyroid glands. The latter may be used to confirm that the tissue identified is actually parathyroid tissue through staining for parathyroid hormone (PTH).

**Side effects:**

None except local irritation by scanning. If biopsies are performed, pain, bleeding, and infection may be seen in rare cases.

Fig. 1: Normal anatomy of the parathyroid glands

### Thyroid and Parathyroid Glands

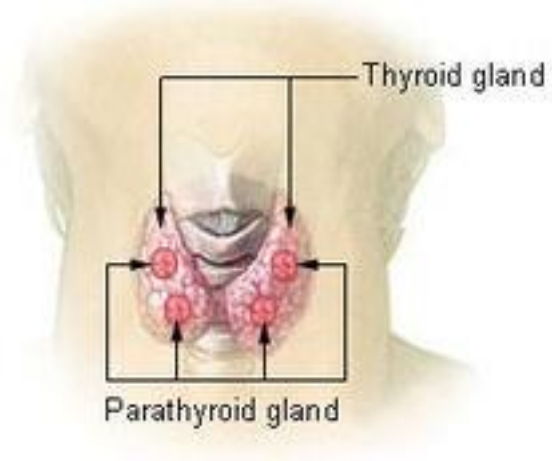
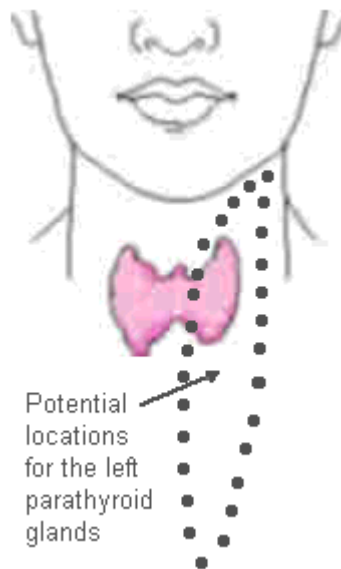


Fig. 2: Variations in localisation of parathyroid glands.



## Bibliography

- [1] Gilmour J , Martin W. The weight of the parathyroid glands. *J Pathol Bacteriol* 1937; 44: 431-462.
- [2] Wang C. The anatomic basis of the parathyroid surgery. *Ann Surg* 1976; 183: 271-275.
- [3] Dekker A, Dunsford HA , Geyer SJ. The normal parathyroid gland at autopsy: the significance of stromal fat in adult patients. *J Pathol* 1979; 128: 127-132.
- [4] Akerström G, Grimelius L, Johansson H, Lundqvist H, Pertoft H , Bergström R. The parenchymal cell mass in normal human parathyroid glands. *Acta Pathol Microbiol Scand A* 1981; 89: 367-375.
- [5] Mihai R, Simon D , Hellman P. Imaging for primary hyperparathyroidism--an evidence-based analysis. *Langenbecks Arch Surg* 2009; 394: 765-784.
- [6] Rasmussen K, Larsen L, Arveschoug A, Nielsen J, Vestergaard P, Rønning H et al. . Predictive value of parathyroid scintigraphy in the preoperative evaluation of patients with primary hyperparathyroidism. *Scand J Surg* 2006; 95: 199-204.